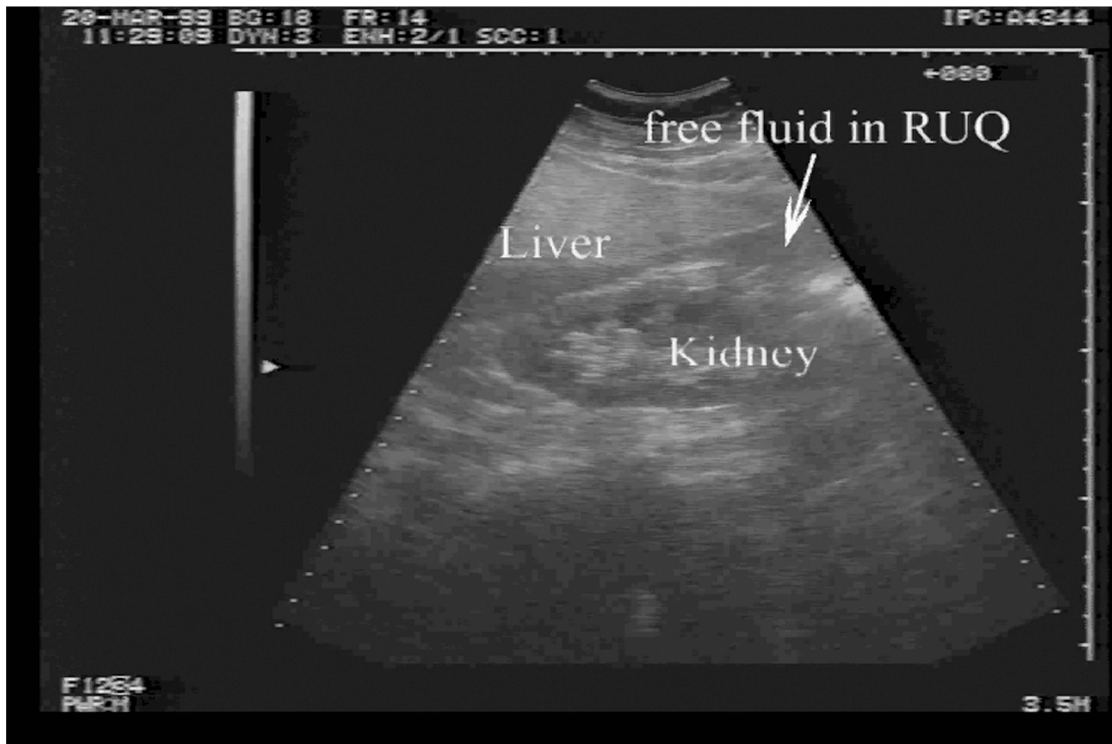
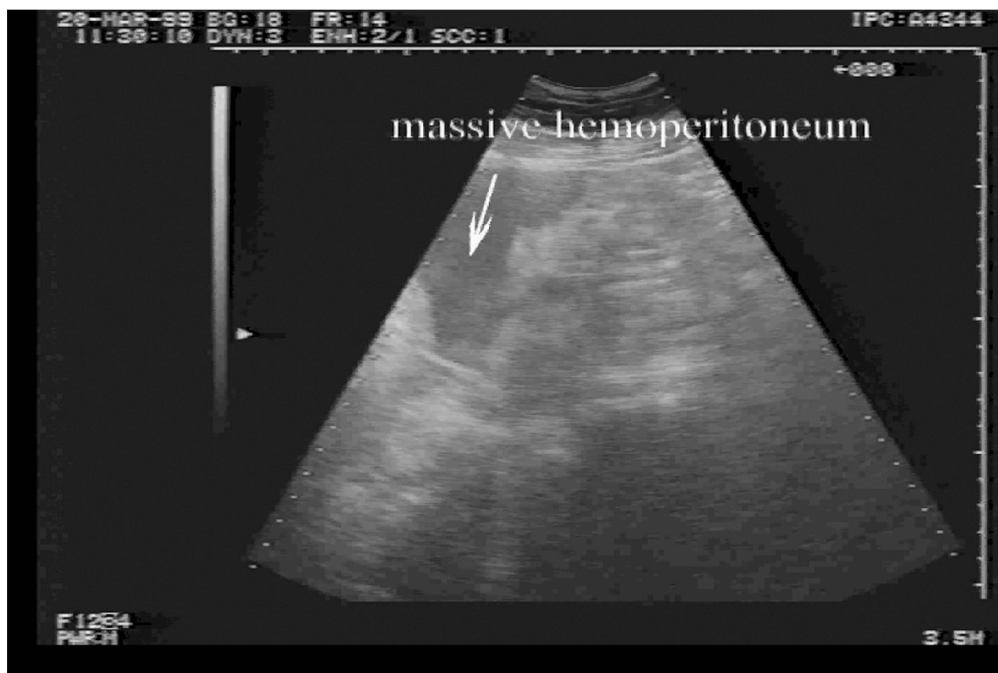


# Case 27

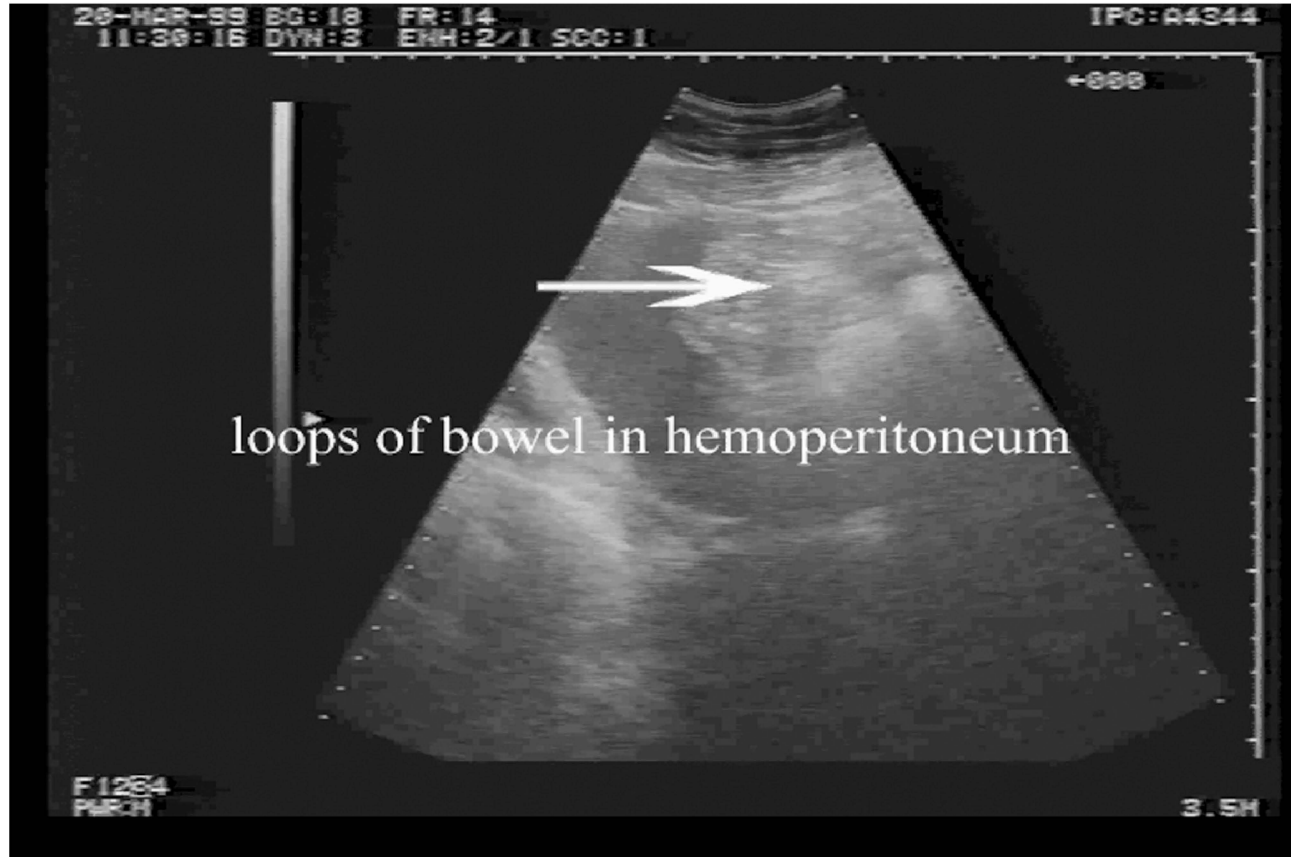


Arrow 1---free fluid in RUQ



Arrow 2---large amount of free fluid in peritoneal space

# Case 27



Arrow 3---loops of bowel floating in hemoperitoneum